

# Melanonychia Striata and the Evaluation of Pigmented Nail Streaks

Biopsy is the key  
to distinguishing between a benign  
and a malignant condition.

BY PETER VANNUCCHI, DPM

## Goals and Objectives

- 1) Identify appropriate hallmarks for distinguishing between benign pigmented nail streaks and subungual malignant melanoma.
- 2) Understand the benefits of performing accurate surgical nail biopsies in order to assist the pathologist in properly identifying malignant melanoma.
- 3) Recognize the causes and simulators of pigmented nail streaks and how the nail apparatus can be a trap to both the patient and the clinician, and why proof of diagnosis is necessary.

Welcome to Podiatry Management's CME Instructional program. Our journal has been approved as a sponsor of Continuing Medical Education by the Council on Podiatric Medical Education.

You may enroll: 1) on a per issue basis (at \$22.00 per topic) or 2) per year, for the special rate of \$169 (you save \$51). You may submit the answer sheet, along with the other information requested, via mail, fax, or phone. You can also take this and other exams on the Internet at [www.podiatrym.com/cme](http://www.podiatrym.com/cme).

If you correctly answer seventy (70%) of the questions correctly, you will receive a certificate attesting to your earned credits. You will also receive a record of any incorrectly answered questions. If you score less than 70%, you can retake the test at no additional cost. A list of states currently honoring CPME approved credits is listed on pg. 198. Other than those entities currently accepting CPME-approved credit, Podiatry Management cannot guarantee that these CME credits will be acceptable by any state licensing agency, hospital, managed care organization or other entity. PM will, however, use its best efforts to ensure the widest acceptance of this program possible.

**This instructional CME program is designed to supplement, NOT replace, existing CME seminars.** The goal of this program is to advance the knowledge of practicing podiatrists. We will endeavor to publish high quality manuscripts by noted authors and researchers. If you have any questions or comments about this program, you can write or call us at: Podiatry Management, P.O. Box 490, East Islip, NY 11730, (631) 563-1604 or e-mail us at [bblock@podiatrym.com](mailto:bblock@podiatrym.com).

Following this article, an answer sheet and full set of instructions are provided (pg. 198).—Editor

### Introduction

The goal of this CME is to present an introduction to the examination of pigmented nail streaks, which are often overlooked and poorly understood in everyday clinical practice. These seemingly benign lesions can

present a difficult clinical challenge because subungual melanoma must always be involved in the differential diagnosis, and quite often a biopsy becomes necessary to confirm what the lesion is. Similarities and differences between melanonychia striata

and subungual melanoma will be addressed and clues to the diagnosis of subungual melanoma are emphasized. Important biopsy techniques applicable are considered and the indication for different surgical ap-

*Continued on page 192*



proaches is emphasized in order to assist the histopathologist in interpreting nail biopsy specimens. Melanonychia striata and longitudinal melanonychia are synonymous terms used in the literature and in most reports, but for purposes of this article, melanonychia striata will be used as more precise and less cumbersome.

### Melanonychia Striata

Melanonychia striata is characterized by a tan, brown, or black longitudinal streak within the nail plate and is a relatively uncommon occurrence. Melanonychia striata results from increased melanin deposits in the nail plate. There are many causes and simulators of melanonychia striata, and it is often impossible to differentiate one another by history and clinical inspection alone. More importantly, subungual malignant melanoma must always be included in the differential diagnosis (Figure 1).

If the causes of melanonychia striata are not apparent, then biopsy is necessary. However, this maxim poses a dilemma. In order to get accurate nail biopsy, tissue must be excised that is both adequate for diagnosis and representative of the underlying pathologic process. In order to minimize the risk of post-operative nail dystrophy, enough matrix must be preserved to permit regeneration of a nail plate that is functionally and cosmetically acceptable. Above all, an accurate interpretation of the biopsy specimen requires broad experience in the evaluation of disorders of the nail unit and its melanocyte system by the histopathologist.

### The Nail Apparatus and Its Melanocyte System

The nail plate is derived from the nail matrix, a spe-

cialized germinative epithelium that lies beneath the proximal nail fold and cuticle. The proximal matrix produces the superior (upper) portion of the nail plate; the distal matrix produces the inferior (lower) portion of

from melanocytes which migrate distally as they transform into nail plate corneocytes. The linear band of the melanized corneocytes is visible in the nail plate.

Melanocytes are normal con-

**Fortunately, the majority  
of these melanocytes are located in the  
distal portion of the nail matrix,  
and because of their greater density and activity,  
pigmented streaks are  
more likely to originate in the distal matrix.**

the nail plate (Figure 2).

Melanonychia striata originates in the nail matrix and results from increased deposition of the melanin

stituents of the nail apparatus, migrate to the nail matrix and bed during embryonic development. Fortunately, the majority of these

melanocytes are located in the distal portion of the nail matrix, and because of their greater density and activity, pigmented streaks are more likely to originate in the distal matrix. This has very important surgical implications because it means that if a surgical biopsy is performed on the distal portion of the matrix and it later forms a defect, that defect will appear on the under-portion of the nail plate and not on the top, and therefore the nail plate surface remains intact.

Sometimes, it is possible to identify the origin (proximal or distal matrix) of pigmentation in melanonychia striata by inspection of the distal nail plate tip after clipping. It is the simplest but least precise method and is generally not a reimbursable procedure. By inspection, pigment localized in the top half of the nail plate indicates proximal matrix origin, and with a subsequent nail defect. When the pigment is in the

*Continued on page 193*

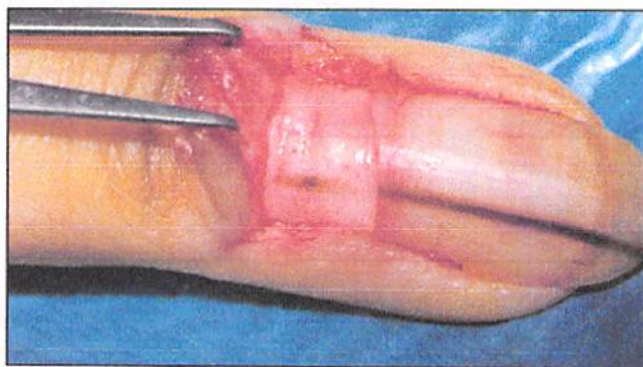


Figure 1: Nevus. Fine melanonychia striata. Reflection of the posterior nail fold permits an easy visualization of the lesion, which is then excised.<sup>1</sup>

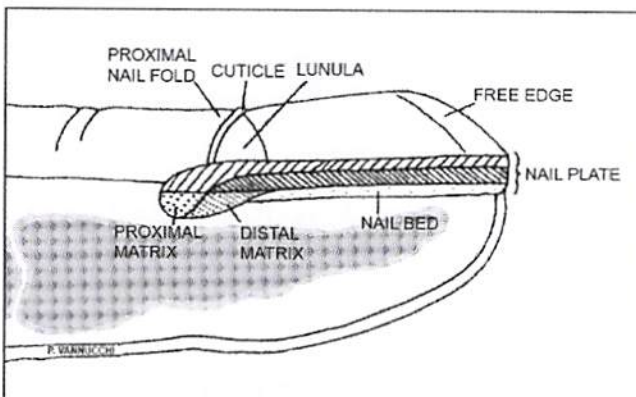


Figure 2: Formation of nail plate. The proximal portion of the nail matrix forms the upper third of the nail plate; the distal matrix forms the lower two thirds of the nail plate. The level of pigment (dorsal or ventral) within the band corresponds to the origin (proximal or distal) within the matrix.<sup>1</sup>



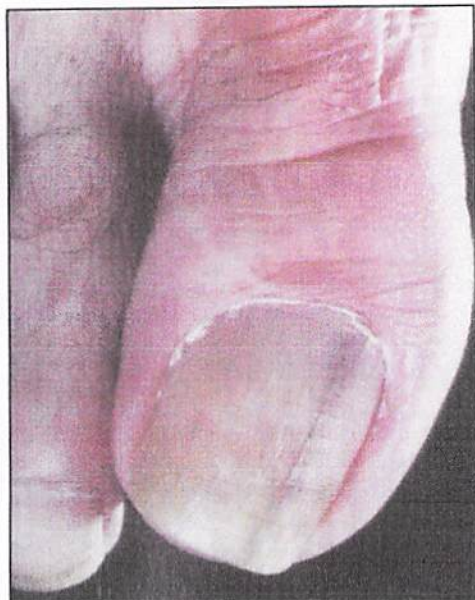

Figure 3: Malignant melanoma. There is a large melanonychia striata that is wider at its base, a good indicator of rapid growth.

bottom half, post-operative dystrophy is less likely.

The level of pigment within the clipped nail specimen may be more accurately ascertained microscopically with Fontana-Masson staining of the nail clipping. This gives an important clue to the pathologist as to precise origin of pigment production and to the appropriate surgical

ma and have a higher incidence of melanonychia striata. Some authors have linked trauma and friction in both the causes of melanonychia striata and subungual melanoma.<sup>3,4,5</sup> But to distinguish the small numbers of patients with subungual melanoma

eign bodies, however, do not follow this rule and require more extensive evaluation.

#### Hutchinson's Sign

Hutchinson's sign represents pigmentation of the nail fold either proximally or laterally and can be an im-

### Occasionally, pigmented nail streaks that are dark brown simulate pigmentation of the overlying cuticle and proximal nail fold.

from the larger group of patients with non-specific melanonychia striata is difficult. Both are alike in several ways. In the hand, each arises most often in the thumb, index fingers, or both. Melanonychia striata has been reported to precede the onset of subungual melanoma and may be an early sign. Both occur commonly in dark pigmented people. By some estimates, 40% to 55% of subungual melanoma arise in the foot, and the majority occur in the great toes. It is not known if it is because of trauma or because the great toe offers a greater surface area. Approximately 3% of malignant

portant indicator for subungual melanoma.<sup>7</sup> But it is not pathognomonic.

Occasionally, pigmented nail streaks that are dark brown simulate pigmentation of the overlying cuticle and proximal nail fold. This pigmentation is visible because of the cuticle and proximal nail fold's transparency, and not because of melanin localization within the tissue. This so-called pseudo-Hutchinson's Sign can be identified by careful inspection and good lighting.

Other less prominent exceptions might include: periungual recurrence of pigmentation after nail surgery or for a nevus, and for malnutrition and minocycline therapy.

Periungual pigmentation and extension, therefore, is a salient but not always specific sign of subungual melanoma, nor does the absence of a Hutchinson's sign mean that the lesion is benign.

Other clues for the diagnosis of subungual melanoma are when melanonychia striata:

- Begin in a single digit during the sixth decade of life or after.
- Develop abruptly in a previously normal nail plate.
- Become suddenly darker or wider.
- Occur in the thumb, index finger, or great toe.
- Occur after digital trauma.
- Occur in a single digit in a dark pigmented patient, especially in the thumb or great toe.
- Demonstrate blurred, rather

*Continued on page 194*

### Subungual melanoma occurs mainly

**in older individuals over more than 50 years of age and appears with equal frequency in both sexes.**

procedure to be selected.<sup>4</sup> But the single most important reason is to determine whether there is a primary melanoma present.

#### Distribution of Melanonychia Striata

Melanonychia striata occurs in 77% of African-Americans more than 20 years of age and in almost 100% who are more than 50 years old. The thumbs and index fingers are common sites as well as the great toes. The more frequently used digits are subject to more trauma

and have a higher incidence of melanonychia striata. Some authors have linked trauma and friction in both the causes of melanonychia striata and subungual melanoma.<sup>3,4,5</sup> But to distinguish the small numbers of patients with subungual melanoma

#### Clues to Diagnosing Subungual Melanoma

A thorough history and physical exam can help distinguish the exogenous causes of a single band of subungual melanoma. Common simulators include subungual hematoma which usually migrates distally. For-



than sharp lateral borders.  
• Occur in a patient with a history of malignant melanoma.

• Occur in a patient when the risk for melanoma is increased (dysplastic nevus syndrome)<sup>8</sup>

• Are accompanied by nail dystrophy such as partial nail destruction or disappearances.

**TABLE 1**  
**Causes of Melanonychia Striata**

Multiple Melanonychia Striata	Single Melanonychia Striata
<b>Drugs and Chemicals</b>	<b>Neoplastic</b>
Antibiotics: cyclines, sulfonamide	<b>Melanocytic</b>
Antimalarials	Malignant melanoma
Antineoplastic drugs	Melanocytic hyperplasia
B-Blocking agents: timolol	Nevus
Heavy metals: arsenic, gold, mercury	<b>Nonmelanocytic</b>
Ketoconazole	Bowen's disease
Phenothiazine	Myxoid cyst
Psoralen	Wart
Zidovudine	<b>Pseudo-Melanonychia Striata</b>
<b>Endocrine</b>	Hemorrhage
Corticotropin therapy	Foreign body
Tumors producing corticotropin or melanocyte-stimulating hormone	Onychomycosis
Addison's disease	
Hyperthyroidism	
Pregnancy	
<b>Ethnic</b>	
Dark-pigmented persons	
<b>Genetic</b>	
Peutz-Jeghers syndrome	
<b>Infections</b>	
Onychomycosis	
<b>Inflammatory</b>	
Lichen planus	
Lichen striatus	
<b>Metabolic and Nutritional</b>	
Hemochromatosis	
Hemosiderosis	
Kwashiorkor	
Vitamin B12 deficiency	
<b>Miscellaneous</b>	
Laugier-Hunziker syndrome	
Carpal tunnel syndrome	
<b>Radiation</b>	
<b>Trauma</b>	
Acute	
Chronic: self-inflicted, onychomania	

Some other important considerations include:

• Black bands may be important consideration in Caucasians for subungual melanoma.

• However, in African-Americans jet-black bands are not unusual.

• Color variation and streaks within streaks may suggest subungual melanoma, but they can be common in multiple benign melanonychia striata.

• Theoretically, wide bands suggest subungual melanoma, but the critical width that signifies melanoma has never been established.

• Bands that do not extend all the way to the free end of the nail are unlikely to be melanomas because they do not take their origin from the nail matrix.

• Bands which are progressively wider indicate rapid growth and are a constant feature of subungual melanoma (Figure 3).

• Multiple pigmented nail streaks are usually not neoplastic in origin.<sup>9</sup> A drug history and complete system review can help rule out systemic disorders as the underlying cause of multiple melanonychia striata (Table 1).

**Pre-operative Consideration for Melanonychia Striata**

Despite meticulous evaluations, too often the cause of melanonychia striata is obscure, and a biopsy becomes necessary. There is no general consensus among pathologists as to the melanocytic causes for melanonychia striata, and therefore, the communication between the clinician and pathologist is critical. The skin pathologist must be provided with a complete history and precise clinical description of the lesion. Photographs are always helpful. It is up to the clinician to provide the pathologist with adequate tissue samples. Nail biopsy interpretation can be difficult, and inadequate tissue sample makes interpretation even more so.

*Continued on page 195*

A biopsy has to be performed correctly the first time; patients should not be subjected to mutilating surgical procedures for a condition that may prove totally benign. But at the same time, the pathologist must be provided with adequate tissue that represents the disorder and adequate for

the pigmented nail streak within the nail plate.

- Band width and matrix origin (proximal or distal).
- Periungual pigmentation when present with melanonychia striata the likelihood of subungual melanoma is greater.

nail and a good to excellent cosmetic result.

#### Mid-portion of the Nail Plate Involvement

When melanonychia striata lie within the mid-portion of the nail plate, the chance for post-operative dystrophy is greater, and the selection of optimal biopsy technique is more difficult. It is important to establish pre-operatively the matrix origin (proximal or distal) of the streak. Because the more proximal the origin, the greater the risk of nail dystrophy. As noted previously, the origin of the longitudinal streak may sometimes be determined by clinical inspection of the nail plate tips or by microscopic examination of Fontana-Masson stained clippings from the distal free edge of the nail. But a more accurate method for establishing the origin of the pigmented streak is by making surgical relaxing incisions in the proximal nail fold and ascertaining the exact location by direct visualization (Figure 1)

These biopsies are best carried out under ring block anesthesia at the base of the digit. The biopsy is then performed with a punch or scalpel. Punch defects smaller than

### The big advantage is that the pathologist is able to study the lesion in its entirety, render a precise diagnosis, and draw salient conclusions regarding prognosis.

diagnosis in order to preclude post-operative recurrence.

No single biopsy method meets the needs of all patients. The following considerations may be helpful in selecting the appropriate biopsy procedure.

- Post-operative nail dystrophy is less likely with distal matrix procedures than with proximal matrix biopsies.

- Complete excision of melanonychia striata with less cosmetic deformity when the band is located in the lateral third of the nail plate.

- When there is periungual spread of pigmentation into the proximal and lateral nail folds, there is a greater likelihood of melanoma, and there should be less regard for cosmetic appearance and more concern for complete lesion extirpation.

- Appearance and functional integrity is less critical in the toes than in the hands.

- Melanonychia striata is more likely to represent subungual melanoma in older patients and biopsy should be performed more aggressively.

#### Biopsy Methods

Among the many surgical procedures for nail biopsies the one that is ultimately selected will depend on:

- The likelihood of subungual melanoma.
- Need to minimize risk of post-operative deformity.
- Location (medial or lateral) of

Imaging studies, both x-rays and/or MRI's, should be obtained, and the patient examined for lymphadenopathy. All infected portions of the nail apparatus (proximal and lateral nail folds, nail plate, nail bed, hyponychium and skin) are removed en bloc down to bone with relative disregard for cosmetic appearance to ensure complete biopsy and excision. The big advantage is that the pathologist is able to study the lesion in its entirety, render a precise diagnosis, and draw salient

conclusions regarding prognosis. The conspicuous disadvantage is significant post-operative deformity.

#### Lateral Portion of Nail Plate Involvement

The preferred surgical technique is a lateral longitudinal biopsy when melanonychia striata involves past the lateral third of the nail plate. The big advantage is that all affected tissue of the nail apparatus are completely removed, and the dermatopathologist can examine the lesion in its entirety. Post-operatively, the patient is left with a narrowed

#### Post-operatively,

### the patient is left with a narrowed nail and a good to excellent cosmetic result.

3mm in diameter need no suture. The punch is run through the soft plate and matrix down to the bone, and the entire specimen is transferred to the fixative. Care should be taken because the matrix tissue is very friable. An antibiotic gauze dressing can then be applied.

#### Wide Plate Nail Involvement

When a wide plate portion of the nail is pigmented, a large portion of the matrix would necessarily be involved. Under these circumstances, the underlying disease process is

*Continued on page 196*



very serious. Depending on the circumstances, partial longitudinal biopsy, transverse elliptic excision, or punch biopsies from selected areas of the matrix can be performed on the entire portion of the nail apparatus, and can be exercised en bloc.

### Malignant Melanoma of the Nail Apparatus

Early diagnosis and surgical removal of the malignant melanoma of the nail and surrounding tissue is necessary to improve currently poor survival rates. The initial assessment staging and follow-up are similar to that for melanomas on other skin sites. Wide local incision of the lesion is recommended. There are no clear surgical guidelines. For malignant melanoma in situ, complete excision of the nail apparatus down to the underlying bone is recommended, followed by a full thickness skin graft. For invasive malignant melanoma, amputation of the digit is required. There seems to be little

streaks which are commonly seen and often overlooked in everyday practice. These enigmatic benign lesions can present a difficult clinical challenge because subungual melanoma mimics melanonychia striata, and biopsies are often necessary to distinguish be-

preparation of this manuscript.

### Endnotes

<sup>1</sup> Abimelel, P. Tumors of the nail Matrix in Atlas of Hair and Nails. 1st. Ed London, Churchill Livingstone. 2000. p. 145.

<sup>2</sup> IBID p. 146

## The nail apparatus can be a trap for both the patient and the clinician, and proof of diagnosis is necessary

tween the two. They should be performed for a single reason: to determine whether there is a primary melanoma.

If there is a pigmented longitudinal nail streak on a toe, then the source of that streak is in the nail matrix, and that is where the biopsy must be performed. A biopsy done anywhere else will result in no information that will help. The nail apparatus can be a trap for both the pa-

<sup>3</sup> Norton, L.A. Incorporation of the Thymidine-Mrthyl-H3 and glycine-2-H3 in the nail Matrix and Bed of Humans. J Invest Dermatol. 1971; 56: 61-68.

<sup>4</sup> Baron, R. Surgery of the Nail. Dermatol Clin. 1984; 2:271-284.

<sup>5</sup> Kopy, A.W., Waldo, E. Melanonychia Striata Australas. J. Dermatol. 1980; 21:59-70.

<sup>6</sup> Daly, J.M., Berlin, R., Urmacher, C. Subungual Melanoma: A 25 year review of cases. J. Surg. Oncol. 1987; 35:107-112.

<sup>7</sup> Mikhail, G.R. Hutchinson's Sign. J. Dermatol Surg. Oncol. 1986; 12:519-521.

<sup>8</sup> Clark Jr, W.C. The Dysplastic Nevus Syndrome. Arch Dermatol. 1988; 124:207-210.

<sup>9</sup> Leppard, B., Sanderson, R. V., Behan, F. Subungual Malignant Melanoma. Difficult in Diagnosis. Br. Med J. 1974; 31-32.

<sup>10</sup> Abimelel, P. Tumors of the nail Matrix in Atlas of Hair and Nails. 1st. Ed London, Churchill Livingstone. 2000. p. 147.

### This article was written to help the clinician identify pigmented nail streaks which are commonly seen and often overlooked in everyday practice.

difference in survival between patients treated with local proximal interphalangeal joint amputation compared to more proximal amputations—provided that adequate excision of the lesion is performed. The level of amputation is chosen to obtain the best functional outcome. Therapeutic lymphadenopathy is advised where there is clinical evidence of metastatic disease in regional lymph nodes.<sup>10</sup> These melanomas are known to metastasize very rapidly to the brain and eye tissue.

### Summary and Conclusion

This article was written to help the clinician identify pigmented nail

streaks which are commonly seen and often overlooked in everyday practice. Proof of diagnosis is necessary. PM

*Disclaimer: Any application of the information in this article in a professional situation remains the professional responsibility of the practitioner. The primary purpose of the author, Dr. Vannucchi is educational. Information presented and surgical techniques discussed are intended to inform the reader about the knowledge, techniques, and experiences of the author. A diversity of professional opinions may exist, and the views of the author are solely his own.*

### Acknowledgments

My appreciation is extended to Patrick Vannucchi for editing and

### Additional Reading

Beaver, D. W., Brooks, S.E. The Nail Colon Atlas of Clinical Diagnosis Year Book. Publishers Inc. Chicago

Pardo-Castello, V., Pardo, Osvaldo. Diseases of the Nails. Charles C Thomas. Springfield, IL 1960



**Dr. Vannucchi** received his professional degree from the New York College of Podiatric Medicine, and completed his post-doctoral studies at the College of Physicians and Surgeons of Columbia University. He completed a surgical fellowship at Fairfield Hospital in Shreveport, Louisiana. Dr. Vannucchi has been in private practice in Corpus Christi, Texas, since 1972, as well as Dallas, Texas.

preparation of this manuscript.



SEE ANSWER SHEET ON PAGE 199.

- 1) Which of the following statements regarding melanonychia striata is correct?
  - A) Melanonychia striata is characterized by a tan, brown, or black longitudinal streak within the nail plate.
  - B) There are many causes and simulators of melanonychia and it is often impossible to differentiate one another solely by history and clinical inspection.
  - C) If the causes of melanonychia striata are not apparent then biopsy is necessary to rule out subungual malignant melanoma.
  - D) All of the above
- 2) Systemic disease(s) that can cause pigmented nail streaks include:
  - A) Addison's Disease
  - B) Hypertension
  - C) Vitamin B12 Deficiency
  - D) All of the above
- 3) Which of the following is more likely to produce a single digit melanonychia striata rather than a multiple digit melanonychia striata?
  - A) Malignant subungual melanoma
  - B) Nevus
  - C) Foreign Body
  - D) All of the above
- 4) Which of the following drugs does not cause multiple digit melanonychia striata?
  - A) Ketoconazole
  - B) Anti-malarials
  - C) Retinoids
  - D) Beta Blocking Agents
- 5) Which of the following is NOT a neoplastic cause for single band melanonychia striata?
  - A) Onychomycosis
  - B) Metastatic Melanoma
  - C) Basal Cell Carcinoma
  - D) Verruca Vulgaris
- 6) Common non-neoplastic causes of melanonychia striata include:
  - A) Pregnancy
  - B) Subungual Foreign Body
  - C) Trauma and Friction
  - D) All of the above
- 7) Which of the following statements regarding nail matrix is correct?
  - A) The nail plate is derived from the nail matrix which lies beneath the proximal nail fold and cuticle.
  - B) Melanonychia striata usually arises in the distal portion of the matrix and not the proximal portion.
  - C) Both A and B
  - D) Neither A or B
- 8) Melanonychia striata is more common in:
  - A) African-Americans
  - B) Hispanics
  - C) Caucasians
  - D) Native Americans
- 9) In the foot subungual melanoma arises more commonly on the \_\_\_\_\_.
  - A) Great toe
  - B) Second toe
  - C) Third toe
  - D) Fourth and fifth toe
- 10) Approximately what percentage of malignant melanomas are subungual in Caucasians?
  - A) 1%
  - B) 3%
  - C) 5%
  - D) 10%
- 11) The median age at which subungual melanoma is diagnosed is \_\_\_\_\_.
  - A) 10 to 20 years
  - B) 20 to 30 years
  - C) 30 to 50 years
  - D) More than 50 years
- 12) The male/female ratio of causes of subungual melanoma is approximately \_\_\_\_\_.
  - A) 1 : 4
  - B) 1 : 2
  - C) 1 : 1
  - D) 2 : 1
- 13) Of the following, the best stain for melanoma pigment is the \_\_\_\_\_.
  - A) S-100 immunoperoxidase stain
  - B) Fontana-masson stain
  - C) Methenamine stain
  - D) Colloidal iron stain
- 14) Hutchinson's sign is \_\_\_\_\_.
  - A) Pigment observed in periungual tissue.
  - B) An important indicator of subungual melanoma but is not pathognomonic.
  - C) Both A and B
  - D) Neither A or B
- 15) When longitudinal nail streaks are dark brown and simulate pigmentation of the overlying cuticle and proximal nail fold because of the skin's transparency, which of the following statements is correct?
  - A) The sign is referred to as pseudo-Hutchinson's sign
  - B) Periungual pigmentation is salient, but always specific
  - C) Malnutrition and certain drugs do not cause pigmented bands and hyper-pigmentation
  - D) After nail surgery for a benign nevus, periungual pigmentation never occurs
- 16) When a nail biopsy is performed for melanonychia striata which of the following statements is true?
  - A) Postoperative nail dystrophy is less likely with proximal matrix procedures than with distal matrix biopsies
  - B) The entire source of the pigment production does not have to be removed
  - C) Biopsy should be performed more aggressively in older patients because the likelihood for subungual melanoma is greater
  - D) Appearance and functional integrity is more important in the toes than in the hands

Continued on page 198



- 17) Which of the following statements is correct?
- A) If you see a longitudinal pigmented nail streak on the nail plate then the source of that streak is in the matrix and that is where you should do your biopsy
  - B) Excision of melanonychia striata is accomplished more easily with less deformity when the streak is located on the lateral portion of the nail rather than on the middle portion
  - C) Both A and B
  - D) Neither A or B
- 18) Which of the following statements is correct?
- A) There are clear surgical guidelines for subungual malignant melanoma
  - B) Band width and matrix location either proximal or distal are important considerations for subungual biopsies
  - C) Periungual spread of pigmentation into the proximal or lateral skin folds is of no clinical significance
  - D) Progressive widening of the pigmented band in melanonychia striata is of no prognostic significance
- 19) Which of the following statements are important considerations for diagnosing subungual melanoma?
- A) Black bands area an important clue to subungual melanoma in Caucasians but not in African-Americans
  - B) Pigmented bands that do not extend to the free end of the nail
  - C) Pigmented bands demonstrate blurred, rather than sharp lateral borders
  - D) All of the above
- 20) Which of the following statements is correct?
- A) Early diagnosis and surgical removal of a malignant melanoma of the nail shows little important survival rates
  - B) There are clear surgical guidelines for subungual malignant melanomas
  - C) Subungual malignant melanomas are known to metastasize very rapidly to the brain and eye tissue
  - D) Periungual pigmentation along with dark black bands of melanonychia striata in a Caucasian patient over 50 years needs no x-rays or MRI's because the cause is usually due to trauma.

See answer sheet on page 199.

## PM's CPME Program

Welcome to the innovative Continuing Education Program brought to you by *Podiatry Management Magazine*. Our journal has been approved as a sponsor of Continuing Medical Education by the Council on Podiatric Medical Education.

### Now it's even easier and more convenient to enroll in PM's CE program!

You can now enroll at any time during the year and submit eligible exams at any time during your enrollment period.

PM enrollees are entitled to submit ten exams published during their consecutive, twelve-month enrollment period. Your enrollment period begins with the month payment is received. For example, if your payment is received on September 1, 2006, your enrollment is valid through August 31, 2007.

If you're not enrolled, you may also submit any exam(s) published in PM magazine within the past twelve months. **CME articles and examination questions from past issues of *Podiatry Management* can be found on the Internet at <http://www.podiatrym.com/cme>.** Each lesson is approved for 1.5 hours continuing education contact hours. Please read the testing, grading and payment instructions to decide which method of participation is best for you.

Please call (631) 563-1604 if you have any questions. A personal operator will be happy to assist you.

Each of the 10 lessons will count as 1.5 credits; thus a maximum of 15 CME credits may be earned during any 12-month period. You may select any 10 in a 24-month period.

**The Podiatry Management Magazine CME program is approved by the Council on Podiatric Education in all states where credits in instructional media are accepted. This article is approved for 1.5 Continuing Education Contact Hours (or 0.15 CEU's) for each examination successfully completed.**

Home Study CME credits now  
accepted in Pennsylvania



# Enrollment/Testing Information and Answer Sheet

**Note:** If you are mailing your answer sheet, you must complete all info. on the front and back of this page and mail with your credit card information to: **Podiatry Management, P.O. Box 490, East Islip, NY 11730.**

## TESTING, GRADING AND PAYMENT INSTRUCTIONS

(1) Each participant achieving a passing grade of 70% or higher on any examination will receive an official computer form stating the number of CE credits earned. This form should be safeguarded and may be used as documentation of credits earned.

(2) Participants receiving a failing grade on any exam will be notified and permitted to take one re-examination at no extra cost.

(3) All answers should be recorded on the answer form below. For each question, decide which choice is the best answer, and circle the letter representing your choice.

(4) Complete all other information on the front and back of this page.

(5) Choose one out of the 3 options for testgrading: mail-in, fax, or phone. To select the type of service that best suits your needs, please read the following section, "Test Grading Options".

## TEST GRADING OPTIONS

### Mail-In Grading

To receive your CME certificate, complete all information and mail with your credit card information to:

**Podiatry Management  
P.O. Box 490, East Islip, NY 11730**

**PLEASE DO NOT SEND WITH SIGNATURE REQUIRED, AS THESE WILL NOT BE ACCEPTED.**

There is **no charge** for the mail-in service if you have already en-

rolled in the annual exam CPME program, and we receive this exam during your current enrollment period. If you are not enrolled, please send \$22.00 per exam, or \$169 to cover all 10 exams (thus saving \$51 over the cost of 10 individual exam fees).

### Facsimile Grading

To receive your CPME certificate, complete all information and fax 24 hours a day to 1-631-563-1907. Your CPME certificate will be dated and mailed within 48 hours. This service is available for \$2.50 per exam if you are currently enrolled in the annual 10-exam CPME program (and this exam falls within your enrollment period), and can be charged to your Visa, MasterCard, or American Express.

If you are not enrolled in the annual 10-exam CPME program, the fee is \$22 per exam.

### Phone-In Grading

You may also complete your exam by using the toll-free service. Call 1-800-232-4422 from 10 a.m. to 5 p.m. EST, Monday through Friday. Your CPME certificate will be dated the same day you call and mailed within 48 hours. There is a \$2.50 charge for this service if you are currently enrolled in the annual 10-exam CPME program (and this exam falls within your enrollment period), and this fee can be charged to your Visa, Mastercard, American Express, or Discover. If you are not currently enrolled, the fee is \$22 per exam. When you call, please have ready:

1. Program number (Month and Year)
2. The answers to the test
3. Your social security number
4. Credit card information

In the event you require additional CPME information, please contact PMS, Inc., at **1-631-563-1604**.

## ENROLLMENT FORM & ANSWER SHEET

Please print clearly...Certificate will be issued from information below.

Name \_\_\_\_\_ Soc. Sec. # \_\_\_\_\_  
Please Print: FIRST MI LAST

Address \_\_\_\_\_

City \_\_\_\_\_ State \_\_\_\_\_ Zip \_\_\_\_\_

Charge to:  Visa  MasterCard  American Express

Card # \_\_\_\_\_ Exp. Date \_\_\_\_\_

**Note: Credit card is the only method of payment. Checks are no longer accepted.**

Signature \_\_\_\_\_ Soc. Sec. # \_\_\_\_\_ Daytime Phone \_\_\_\_\_

State License(s) \_\_\_\_\_ Is this a new address? Yes  No

**Check one:**  I am currently enrolled. (If faxing or phoning in your answer form please note that \$2.50 will be charged to your credit card.)

I am not enrolled. Enclosed is my credit card information. Please charge my credit card \$22.00 for each exam submitted. (plus \$2.50 for each exam if submitting by fax or phone).

I am not enrolled and I wish to enroll for 10 courses at \$169.00 (thus saving me \$51 over the cost of 10 individual exam fees). I understand there will be an additional fee of \$2.50 for any exam I wish to submit via fax or phone.





**EXAM #9/12**  
**Melanonychia Striata and the**  
**Evaluation of Pigmented Nail Streaks**  
**(Vannucchi)**

Circle:

- |             |             |
|-------------|-------------|
| 1. A B C D  | 11. A B C D |
| 2. A B C D  | 12. A B C D |
| 3. A B C D  | 13. A B C D |
| 4. A B C D  | 14. A B C D |
| 5. A B C D  | 15. A B C D |
| 6. A B C D  | 16. A B C D |
| 7. A B C D  | 17. A B C D |
| 8. A B C D  | 18. A B C D |
| 9. A B C D  | 19. A B C D |
| 10. A B C D | 20. A B C D |

**LESSON EVALUATION**

Please indicate the date you completed this exam

\_\_\_\_\_

How much time did it take you to complete the lesson?

\_\_\_\_\_ hours \_\_\_\_\_ minutes

How well did this lesson achieve its educational objectives?

\_\_\_\_\_ Very well \_\_\_\_\_ Well

\_\_\_\_\_ Somewhat \_\_\_\_\_ Not at all

What overall grade would you assign this lesson?

A B C D

Degree \_\_\_\_\_

Additional comments and suggestions for future exams:

\_\_\_\_\_  
\_\_\_\_\_  
\_\_\_\_\_  
\_\_\_\_\_  
\_\_\_\_\_  
\_\_\_\_\_